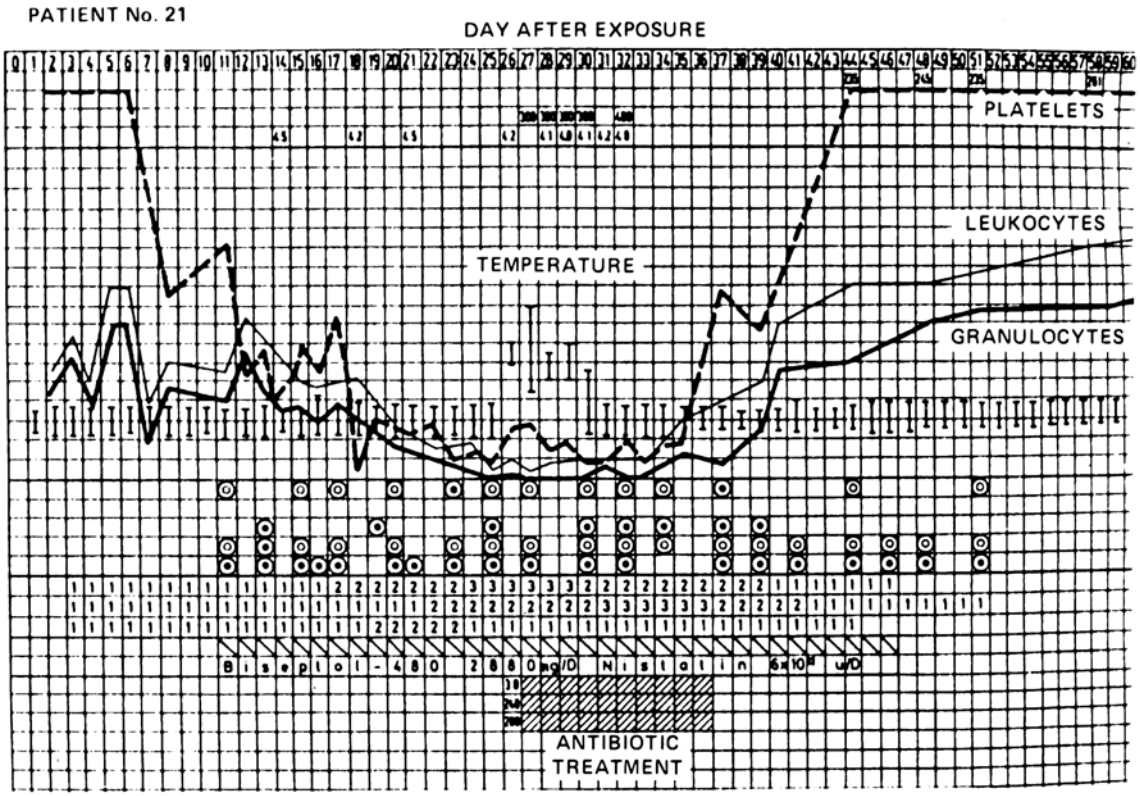

Figure 5-2. Medical chart of a victim of the Chernobyl reactor disaster, illustrating occurrence of infection associated with granulocytopenia.

Back